

# Splanchnic Perfusion During Induced Hypotension and ANH in Spinal Surgery

I. Čundrle, H. Ondrášková, R. Gál, B. Stibor

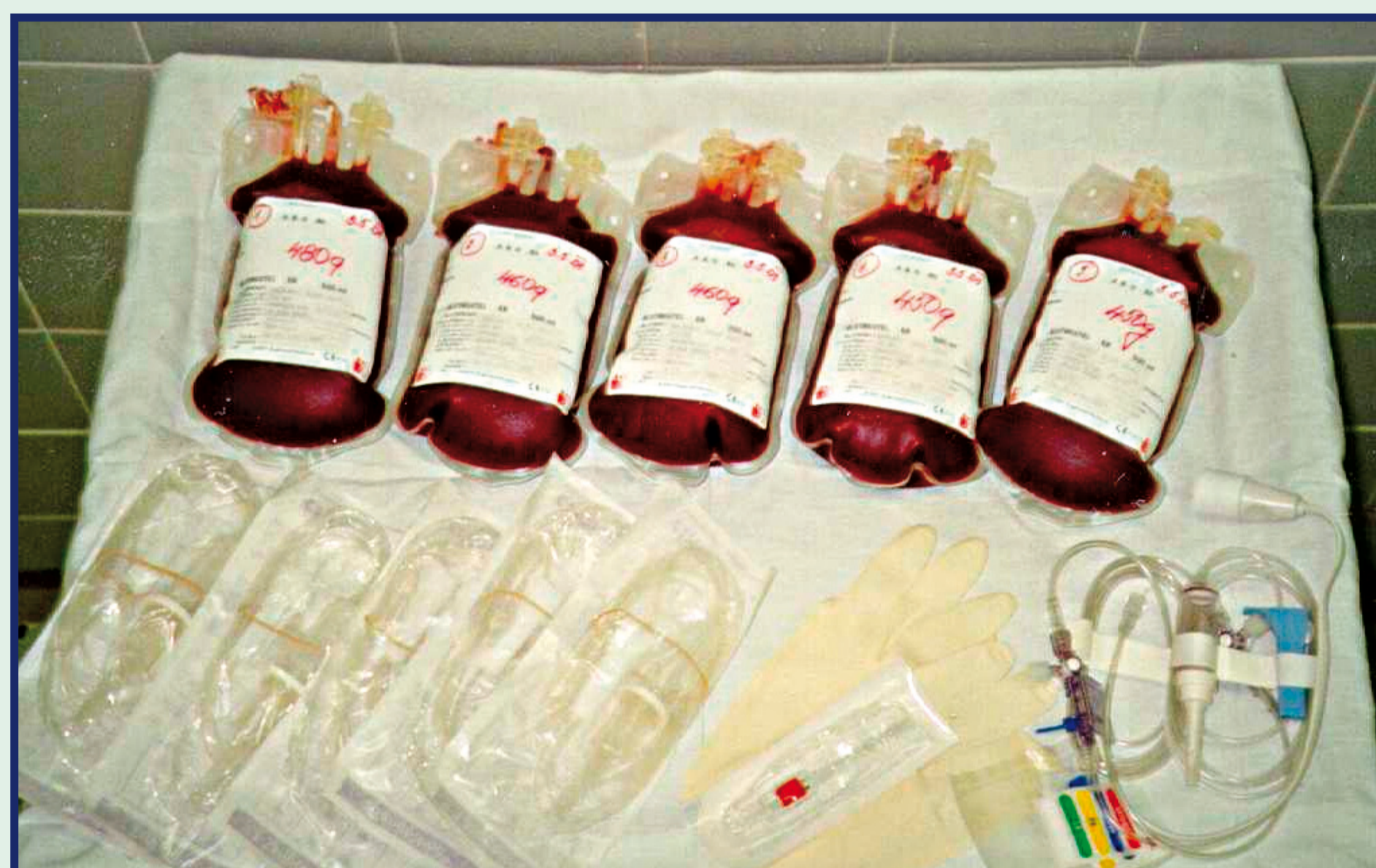Department of Anaesthesiology and Intensive Care, Brno, Czech Republic

## CSBM

The Czech Society of Bloodless Medicine

## Introduction

Induced hypotension in spinal surgery is – in spite of various objections (1) – one of the methods, which save the patient's blood. All authors agree that the MAP borderline should not be lower than 60 torr. Only one work, however, is concerned with splanchnic perfusion during controlled hypotension (2). Acute normovolemic hemodilution is one of standard methods of bloodless medicine.



P.1: Acute normovolemic hemodilution is one of standard methods of bloodless medicine

## Methods

Controlled hypotension to the MAP level of 60 torr using sodium nitroprusside (p.1) was applied to 20 patients with identical demographic data, diagnosed with idiopathic scoliosis, the same number of fused vertebrae, without disorders of coagulation, blood count, kidney or liver functions (p.2) Before and after anaesthesia without volatile anaesthetics, blood samples for ICG-PDR were taken and measured with the LIMON apparatus (p.3).

A control homogenous group of 20 patients was selected.

Twenty patients who did not undergo treatment with bloodless medicine represented a control group regarding the diagnosis and the laboratory results.

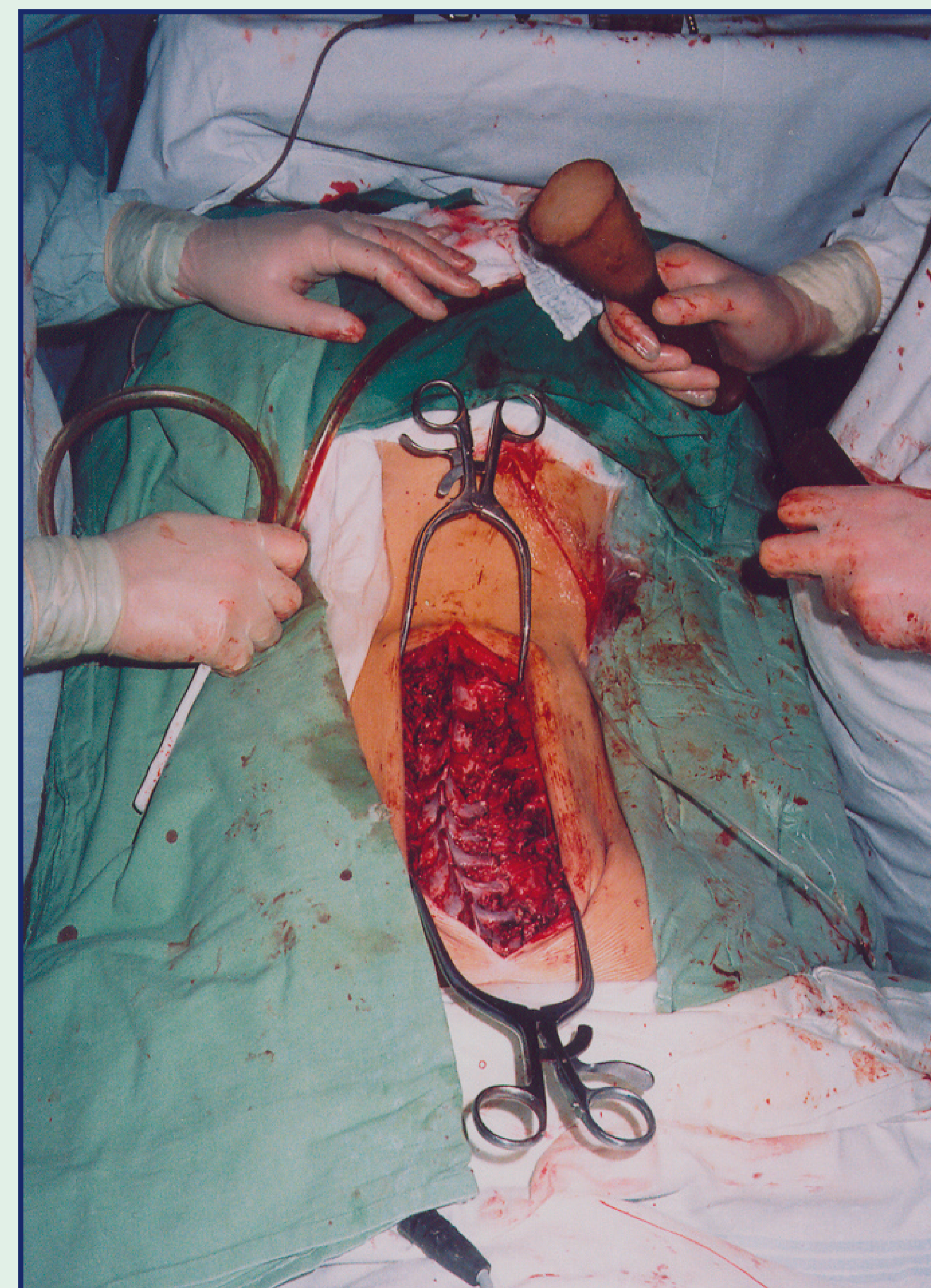
The results were statistically processed by the t-test for unpaired values. A value  $p < 0.05$  was evaluated as statistically significant.

## Results

No statistical significance between both groups was proved. In the hypotension group the level of PCG-PDR was higher than 18%/min (p.4). Haemorrhage in ANH did not manifest itself in the studied group.

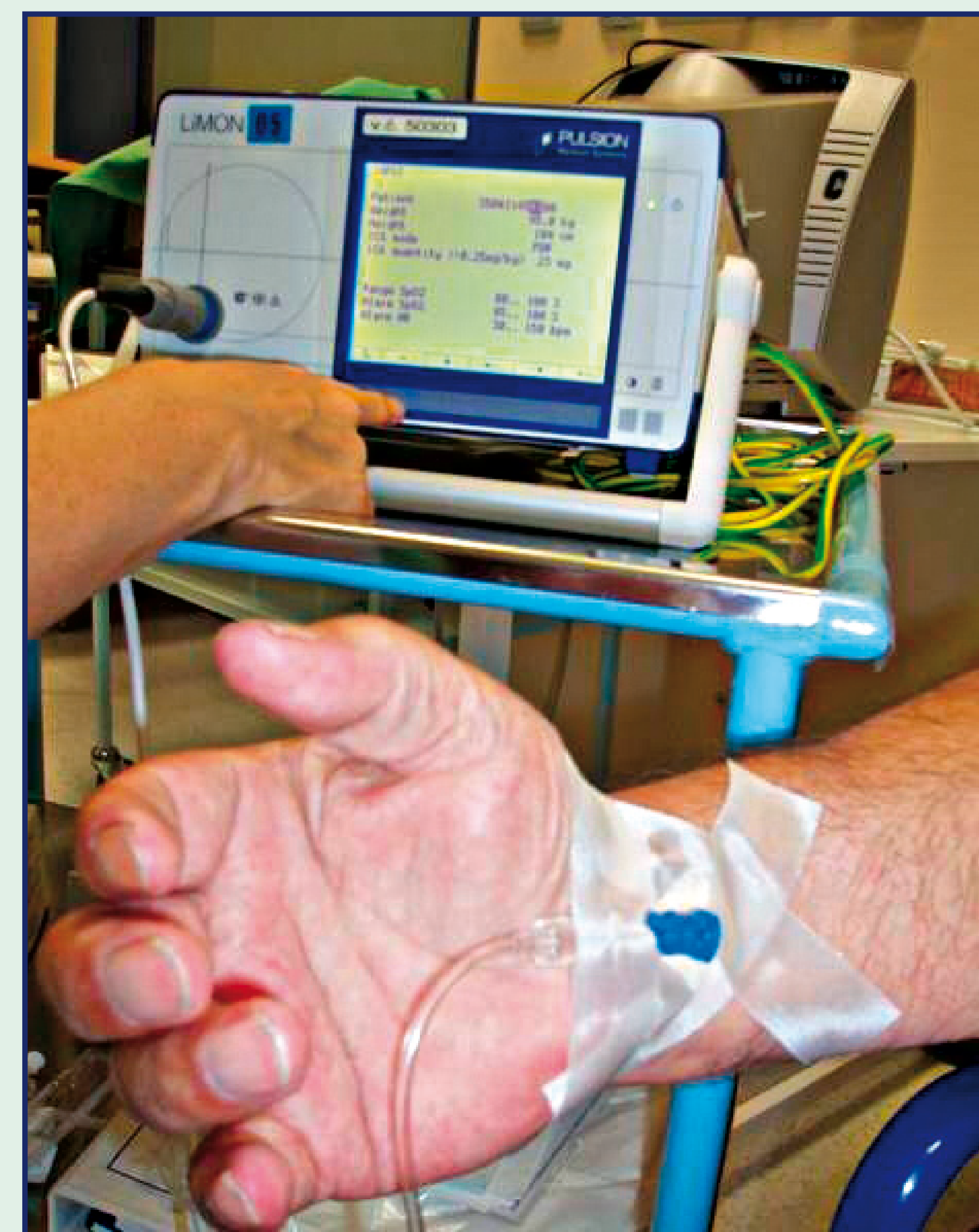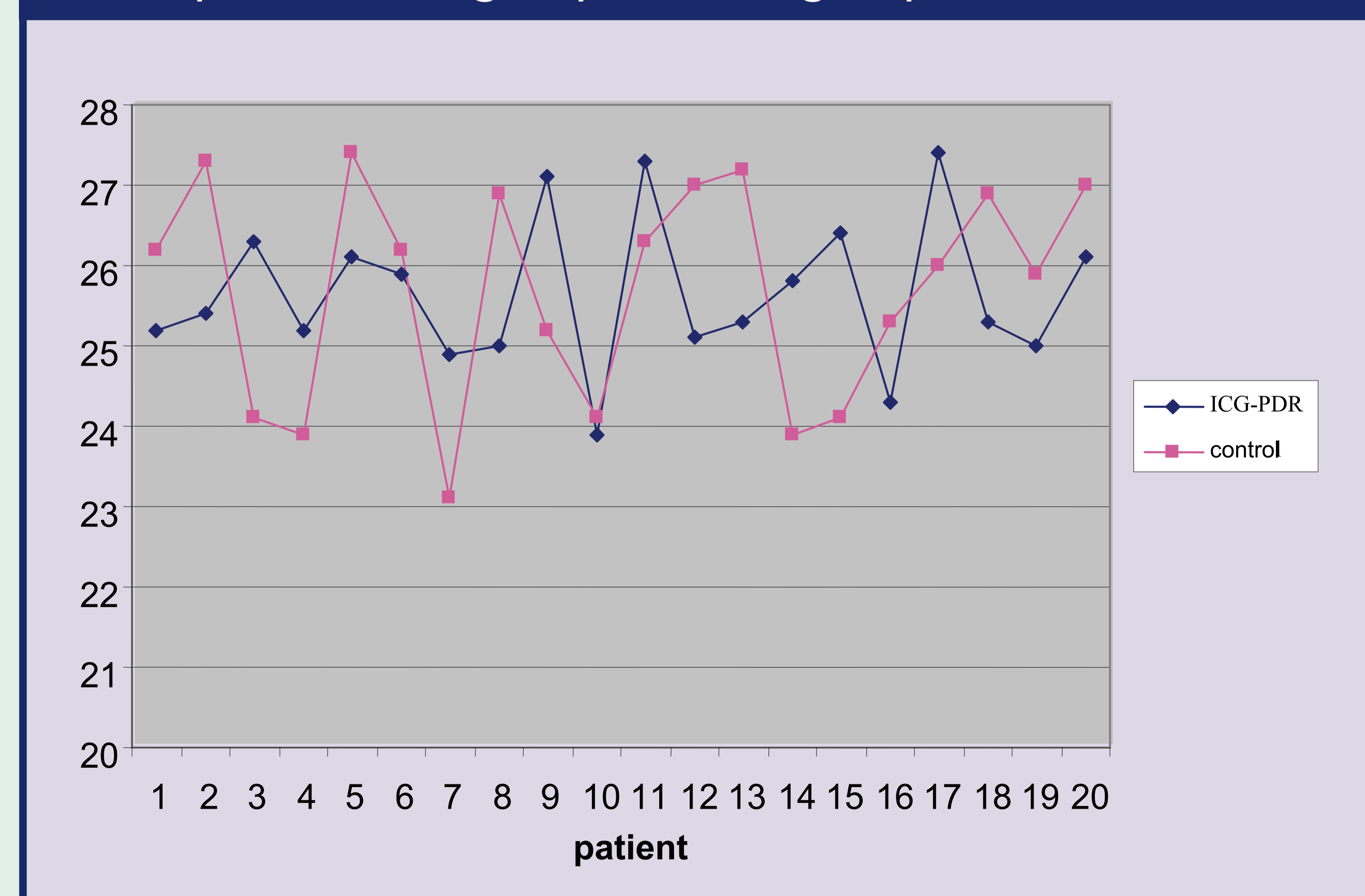
## Conclusion

PCG-PDR is among the indicators of perfusion of the splanchnic area. Our results provide evidence of its good perfusion during artificial lowering of MAP to the level of 60 torr with the help of a substance with exceptionally good vasodilatation properties. The results have also proved that the combination of induced hypotension and ANH is safe.



P.2: The spinal surgery with induced hypotension

P.4: Graph ICG-PDR group/ control group



P.3: LIMON apparatus for ICG-PDR examination

## Literature:

1. Spahn, D.R., Casutt, M.: Eliminating blood transfusions: New aspects and perspectives. *Anesthesiology*, 2000, 93, 242-255
2. Fukusaki, H. et al.: Splanchnic perfusion during controlled hypotension with hemodilution under isoflurane anaesthesia in elderly patients. *European Journal of Anaesthesiology*, 1999, 16, 519-525